

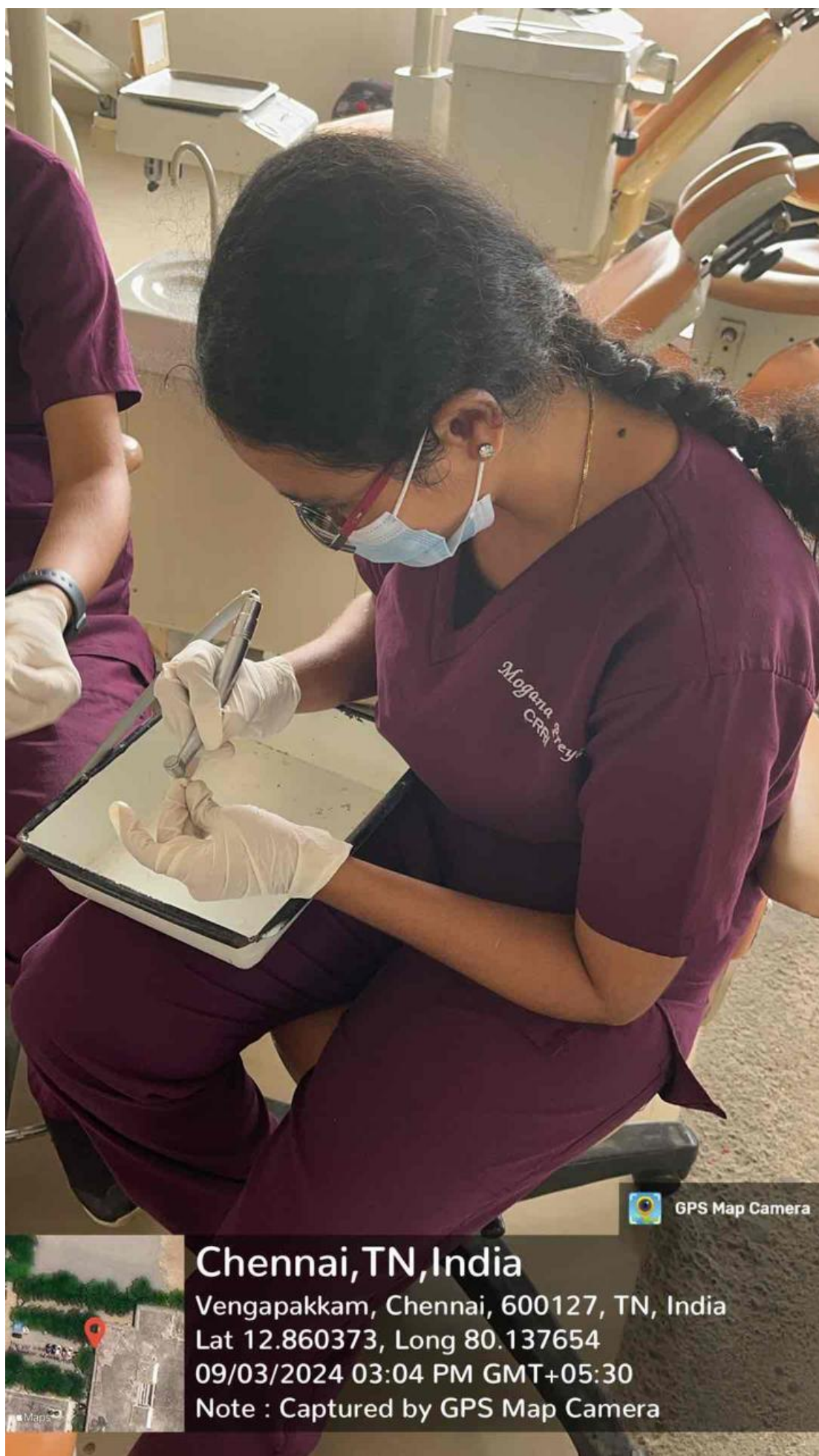
CLINICAL ENDODONTICS- ROOT CANAL COURSE

CONSERVATIVE AND ENDODONTICS DEPARTMENT


02/09/2024 AND 03/09/2024



Clinical Endodontics- root canal course was conducted on sept 2 and 3, 2024 at conservative and Endodontics departmentt seminar hall. Around 24 students actively participated in the course. Department staff took lecture on basics of root canal treatment procedure, protocols and management. It was followed by hands-on demo by all staffs yesterday and today students did on practical demo of RCT under the guidance of all staff. 2 clinical patient cases will be done by all students who have registered in the following days under the supervision of the endo department staff.



GPS Map Camera



Chennai, TN, India

Vengapakkam, Chennai, 600127, TN, India

Lat 12.860373, Long 80.137654

09/03/2024 03:04 PM GMT+05:30

Note : Captured by GPS Map Camera



SUPPLEMENTAL INJECTION TECHNIQUES

Supplemental injections are essential when, as frequently occurs, anesthesia from conventional technique is inadequate and the pain is too severe for the endodontic or dental procedure.

Intra-ligamentary Injection	Intra-osseous Injection	Intra-pulpal Injection
Local anesthetic is delivered directly into the periodontal space surrounding the tooth.	Deposition of local anesthetic into the bone.	Deposition of local anesthetic into the pulp space.
ADVANTAGES: <ul style="list-style-type: none">• Rapid onset of action• Minimal volume• Minimal risk of infection	ADVANTAGES: <ul style="list-style-type: none">• Rapid onset of action• Minimal volume• Minimal risk of infection	ADVANTAGES: <ul style="list-style-type: none">• Rapid onset of action• Minimal volume• Minimal risk of infection
DISADVANTAGES: <ul style="list-style-type: none">• Painful• Risk of infection• Risk of pulp necrosis	DISADVANTAGES: <ul style="list-style-type: none">• Painful• Risk of infection• Risk of pulp necrosis	DISADVANTAGES: <ul style="list-style-type: none">• Painful• Risk of infection• Risk of pulp necrosis

Dr. S. Ravi Kumar
Dentist
S. Ravi Kumar
Dentist

GPS Map Camera

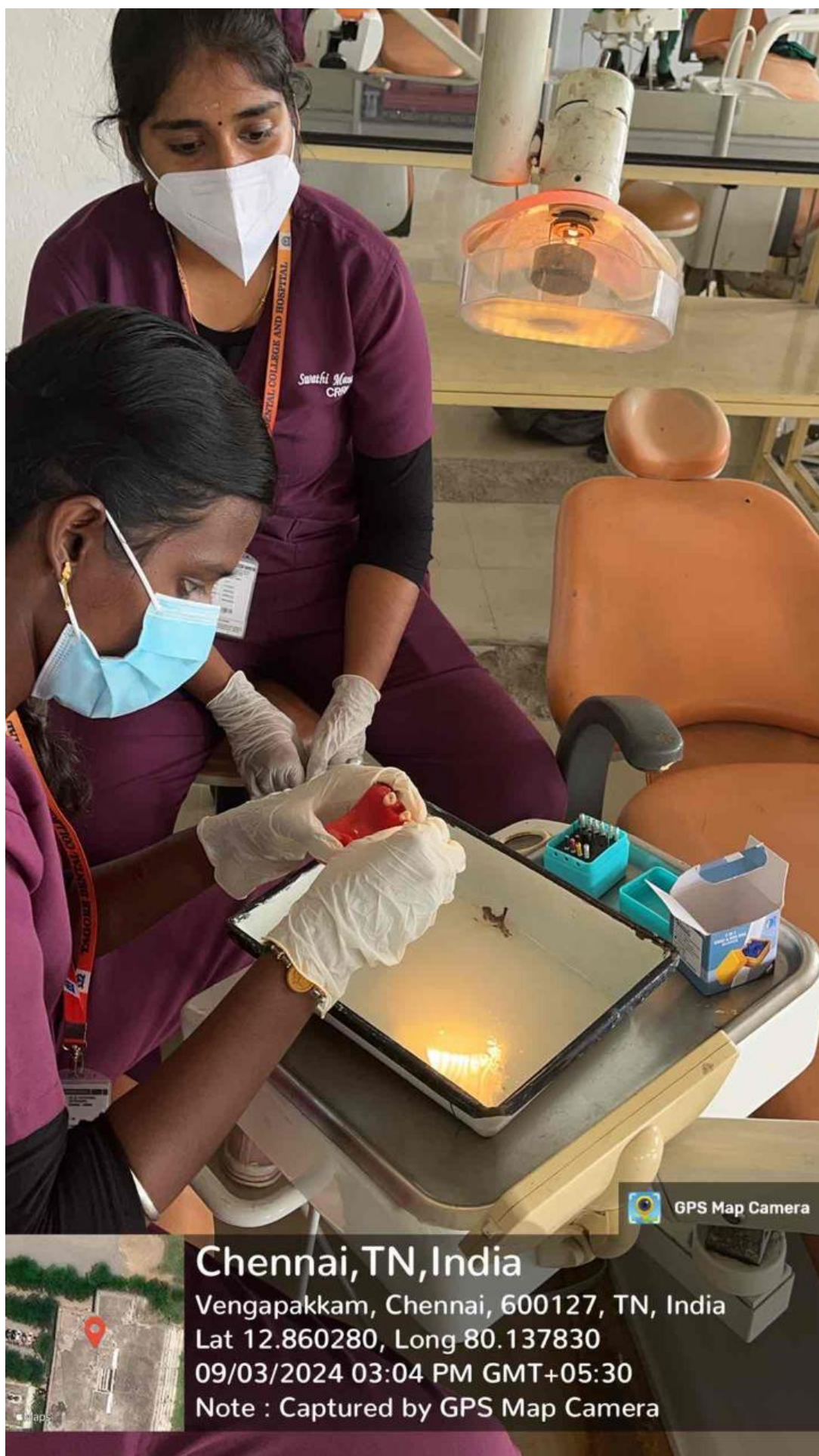
Chennai, TN, India

Vengapakkam, Chennai, 600127, TN, India

Lat 12.860284, Long 80.137590

09/03/2024 03:03 PM GMT+05:30

Note : Captured by GPS Map Camera



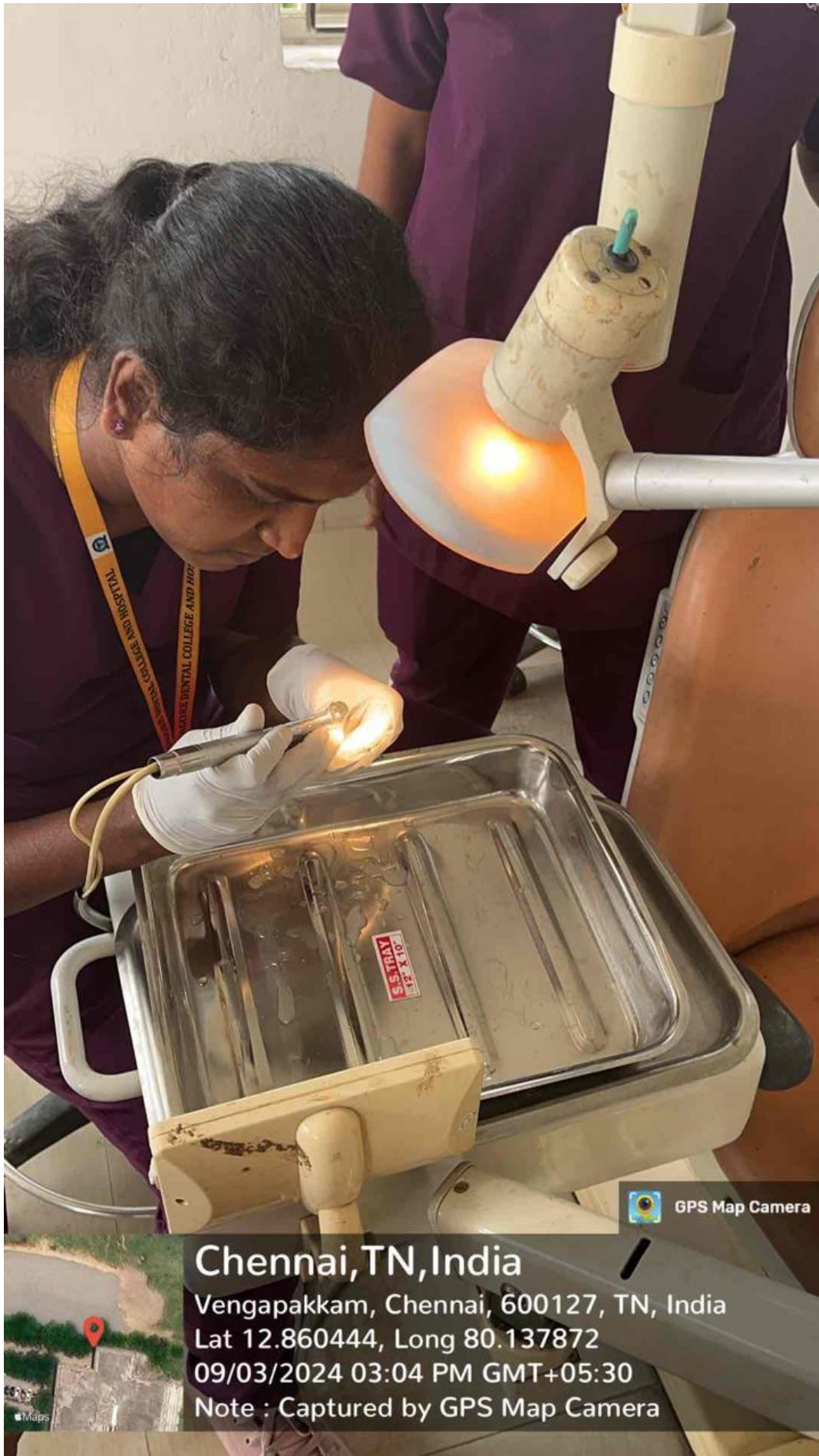Chennai, TN, India

Vengapakkam, Chennai, 600127, TN, India

Lat 12.860280, Long 80.137830

09/03/2024 03:04 PM GMT+05:30

Note : Captured by GPS Map Camera



GPS Map Camera

Chennai, TN, India

Vengapakkam, Chennai, 600127, TN, India

Lat 12.860444, Long 80.137872

09/03/2024 03:04 PM GMT+05:30

Note : Captured by GPS Map Camera

